

## Evaluating the reliability of vastus medialis thickness measurement using B-mode ultrasound: a one-week interval study

Maciej Biały<sup>1,2(A,C,D,E,F)</sup>, Patryk Marczykowski<sup>3(A,B,C,D)</sup>, Bartosz Wilczyński<sup>4(A,C,E,F)</sup>,  
Jenny McConnell<sup>5,6(A,D,E,F)</sup>

<sup>1</sup>Institute of Physiotherapy and Health Sciences, Academy of Physical Education, Katowice, Poland

<sup>2</sup>Functional Diagnostics Laboratory, Sport-Klinika, Scanmed Sport, Żory, Poland

<sup>3</sup>Iga Garbowska Osteopathy Clinic, Katowice, Poland

<sup>4</sup>Department of Immunobiology and Environment Microbiology, Medical University of Gdańsk, Gdańsk, Poland

<sup>5</sup>McConnell Physiotherapy Group, Mosman, Australia

<sup>6</sup>Center for Health Exercise and Sports Medicine, University of Melbourne, Melbourne, Australia

### Authors' contribution:

- A. Study design/planning
- B. Data collection/entry
- C. Data analysis/statistics
- D. Data interpretation
- E. Preparation of manuscript
- F. Literature analysis/search
- G. Funds collection

Tables: 2

Figures: 1

References: 26

Submitted: 2025 Aug 14

Accepted: 2025 Sep 19

Published Online: 2025 Sep 24

### Abstract

**Background.** The vastus medialis (VM) muscle is essential for patellofemoral joint stability, and its dysfunction is linked to multiple knee disorders. Ultrasound (US) offers a practical method for VM assessment. The reliability of longitudinal-plane thickness measurements by novice examiners remains unclear.

**Material and methods.** 18 healthy adults (mean age 23.5±1.25 years) underwent three VM thickness measurement sessions: two on the same day and one after one week. Measurements at rest (R) and during maximal voluntary isometric contraction (MVIC) were obtained using a standardized protocol. Intra-class correlation coefficients (ICCs), standard error of measurement (SEM), and smallest detectable difference (SDD) were calculated to assess intra-rater reliability.

**Results.** Single-session measurements achieved excellent reliability (ICC≥0.93) for both R and MVIC, with greater precision from averaging multiple registrations. One-week interval measurements showed moderate-to-good reliability (ICC 0.52-0.87), improving with repeated measurements. Mean VM thickness increased from 27.1±3.9 mm (R) to 32.4±4.6 mm (MVIC).

**Conclusions.** Longitudinal US measurement of VM thickness is highly reliable within a single session, especially when multiple images are averaged. Consistent landmarks, standardized procedures, and examiner training can enhance long-term measurement reliability in clinical and research settings.

**Keywords:** muscle thickness, knee rehabilitation, vastus medialis, reliability, ultrasound

### Introduction

Vastus medialis muscle (VM) plays a critical role in the functional stability of the patellofemoral joint (PFJ), which is mainly based on the counterstrain for vastus lateralis torques and optimizing patellar tracking within the

Biały M, Marczykowski P, Wilczyński B, McConnell J. Evaluating the reliability of vastus medialis thickness measurement using B-mode ultrasound: a one-week interval study. *Health Prob Civil.* 2026; 20(2): 207-214. <https://doi.org/10.5114/hpc.2025.154552>

**Address for correspondence:** Maciej Biały, Institute of Physiotherapy and Health Sciences, Academy of Physical Education, Mikołowska Street 72A, 40-065 Katowice, Poland, e-mail: mbfizjoterapia@gmail.com

ORCID: Maciej Biały <https://orcid.org/0000-0001-8150-7513>, Bartosz Wilczyński <https://orcid.org/0000-0002-8663-3698>, Jenny McConnell <https://orcid.org/0000-0001-6945-4447>

Copyright: © Maciej Biały, Patryk Marczykowski, Bartosz Wilczyński, Jenny McConnell. This is an Open Access journal, all articles are distributed under the terms of the Creative Commons AttributionNonCommercial-ShareAlike 4.0 International (CC BY-NC-SA 4.0) License (<https://creativecommons.org/licenses/by-nc-sa/4.0/>), allowing third parties to copy and redistribute the material in any medium or format and to remix, transform, and build upon the material, provided the original work is properly cited and states its license.

trochlear groove [1]. There are various clinical conditions that contribute to the impairment of the VM, which, without an appropriate diagnosis and treatment approach, may end up with the chronic inhibition of this muscle unit and finally result in PFJ dysfunction [2]. It has been shown that in patients with knee osteoarthritis, VM degeneration is associated with cartilage loss and worsening PFJ symptoms [3,4]. VM atrophy was also found in people with patellofemoral pain syndrome (PFPS) when compared to an asymptomatic population [5,6]. Additionally, preoperative VM thickness measurement can predict the development of postoperative PFPS in patients after arthroscopic partial meniscectomy [7]. After anterior cruciate ligament (ACL) reconstruction, some patients experience activation failure and reduced ability of the VM to contract. This condition, known as arthrogenic muscle inhibition (AMI), refers to a neural inhibition of the quadriceps femoris muscle [8,9]. Although its exact mechanisms are not fully understood, AMI is generally thought to result from abnormal sensory input originating from a post-operation knee joint [10]. This altered input disrupts normal motor control and can negatively affect both short- and long-term postsurgical outcomes [11,12]. In chronic conditions, prolonged AMI contributes to changes in muscle architecture [13], disturbances in muscle growth and strength gains [14], and can ultimately delay the desired recovery time [15]. Considering the aforementioned studies, it seems that early diagnosis of VM dysfunction may be critical in various clinical conditions and presents a significant challenge for clinicians.

Ultrasound (US) imaging for muscle assessment has gained prominence in musculoskeletal research and clinical practice, demonstrating its use across diverse populations and conditions [16-19]. According to sonographic VM measurement, its thickness is considered as valid and reliable as magnetic resonance imaging (MRI) and serves as an objective tool for VM assessment [20,21]. Evaluation of VM function with the use of US typically involves three metrics: cross-sectional thickness [22], cross-sectional area (CSA) [21], and pennation angle [23].

### **Aim of the work**

This study aimed to determine whether VM thickness in the longitudinal section is a reliable measure and can be used as an additional metric. We evaluated intra-rater measurement reliability, with US measurements taken during two sessions and a third taken after a one-week interval by an examiner with a low level of experience in sonographic musculoskeletal assessment.

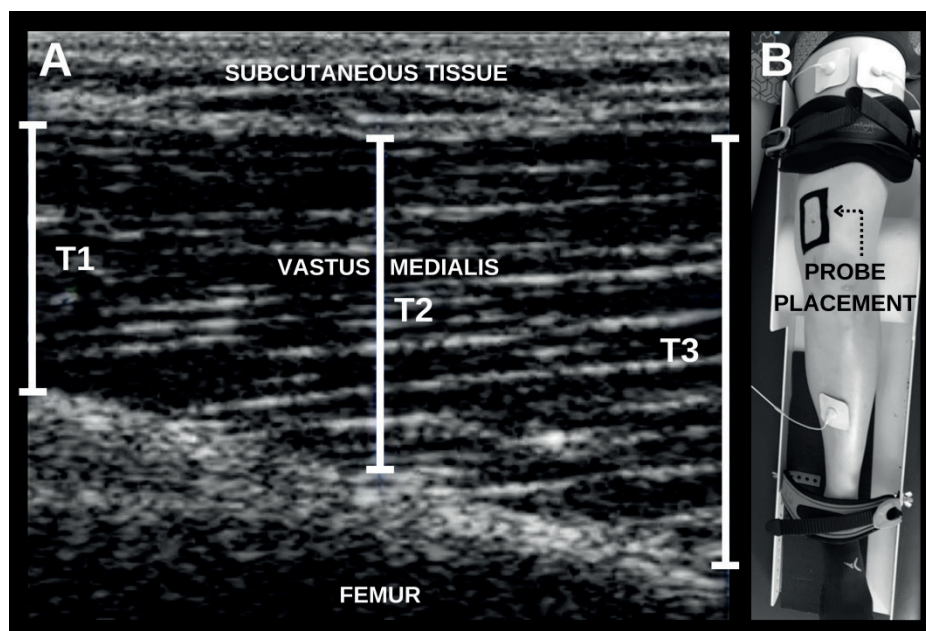
### **Material and methods**

This descriptive laboratory study assessed the intra-rater reliability of VM thickness measurements in healthy participants. Measurements included VM thickness at rest (R) and during maximal voluntary isometric contraction (MVIC). Three sessions were conducted: two on the first day with a 5-minute break and the third after a one-week interval. The examiner underwent basic training from an experienced US specialist prior to the study.

18 healthy participants (3 males) completed the study, with a mean age of  $23.5 \pm 1.25$  years, height  $1.71 \pm 0.11$  m, weight  $67.5 \pm 15.57$  kg, and BMI  $22.83 \pm 3.24$ . Based on previous reliability studies of quadriceps US [22], a minimum of 16 participants was sufficient to obtain stable intra-class correlation coefficients (ICC) values. Inclusion required participants to be 18 y.o. or older, and the exclusion criteria were: history of lower extremity surgery, neurological disorders, and current pain/injury in the past month. VM images were collected during R and MVIC using a DP 6600 US device (Mindray, Shenzhen, China) with a 38 mm linear-array probe (5-10 MHz). The scanner settings were standardized across all measurements: depth

4 cm, a single focal zone positioned at the mid-belly of the vastus medialis (~2 cm below the skin surface), overall gain 50%, and dynamic range 70 dB. The reference point was 80% of the distance between the anterior superior iliac spine and the joint space (medial tibiofemoral joint line, which was identified by palpation) [24]. To ensure consistent knee positioning at 15° flexion, a foam roller and straps stabilized the leg, and the US probe was secured with elastic tape for repeatability. Generous US gel was used to minimize tissue compression.

The quadriceps femoris MVICs were performed in a standardized supine position against a fixed resistance. Each contraction was maintained for 5 seconds, followed by 60 seconds of rest to avoid fatigue. During each session, six MVIC trials were performed, yielding six US images during contraction and six at rest (12 images per session, 36 images per participant in total). Surface electromyography (sEMG) with electrodes placed on the quadriceps femoris provided real-time visual feedback to ensure stable contractions. The trial images were blinded before analysis. VM thickness was measured at three points (left edge, right edge, midpoint) per image, and the mean value was used for further analysis. Thickness measurement and the lower extremity position during image registration is presented in Figure 1.



**Figure 1.** Panel A: US image showing VM thickness key measurement points: T1 (left edge), T2 (midpoint), and T3 (right edge), with marked subcutaneous tissue and femur bone; Panel B: Probe placement setup at the standardized reference point on the participant's thigh

ICCs were calculated using a mixed-model ANOVA. ICC (3, k) values assessed intra-rater reliability over repeated sessions on the same day (intra-rater 1) and after a one-week interval (intra-rater 2). Reliability was classified as poor (<0.5), moderate (0.5-0.75), good (0.75-0.9), or excellent (>0.9) [25]. Confidence intervals (95% CI), the standard errors of measurement ( $SEM = SD \times (1 - ICC)^{1/2}$ ) and the smallest detectable differences ( $SDD = SEM \times 1.96 \times 2^{1/2}$ ) were calculated using Statistica (Version 13; TIBCO Software Inc., Palo Alto, CA, USA) and SPSS (IBM Corp., Armonk, NY, USA) software. Two same-day sessions assessed short-term repeatability, while the third session (one week later) assessed test-retest reliability over time.

## Results

For intra-rater 1 reliability at VM R conditions, the ICCs ranged from 0.93 (95% CI: 0.84-0.97) for a single registration to 0.98 (95% CI: 0.94-0.99) when averaging up to six registrations. The corresponding SEM and SDD values decreased from 1.1 mm for a single registration to 0.6 mm for six registrations and from 3.0 mm to 1.6 mm, respectively. Under VM MVIC conditions, intra-rater 1 reliability demonstrated high ICC values, ranging from 0.93 (95% CI: 0.82-0.97) for a single registration to 0.98 (95% CI: 0.94-0.99) with six registrations. The SEM and SDD values decreased from 1.3 mm for a single registration to 0.7 mm for six registrations, and from 3.6 mm to 1.8 mm, respectively. For intra-rater 2 reliability at VM R, the ICCs were lower, starting at 0.52 (95% CI: 0.09-0.79) for a single registration and improving to 0.81 (95% CI: 0.49-0.93) with six registrations. Similarly, the SEM and SDD values decreased from 2.8 mm for a single registration to 1.8 mm for six registrations, and from 7.9 mm to 5.1 mm, respectively. For intra-rater 2 reliability under VM MVIC, ICCs started at 0.74 (95% CI: 0.44-0.89) for a single registration and increased to 0.87 (95% CI: 0.67-0.95) with six registrations. Corresponding SEM and SDD values improved from 2.5 mm to 1.8 mm and 7.1 mm to 4.9 mm, respectively. All the ICC values, SEMs, and SDDs are summarized in Table 1.

**Table 1.** ICCs with 95% CIs, SEMs, and SDDs for VM thickness measurement at rest and during MVIC

Reliability	N registrations	Rest			MVIC		
		ICC ( $\pm$ 95%CI)	SEM (mm)	SDD (mm)	ICC ( $\pm$ 95%CI)	SEM (mm)	SDD (mm)
Intra-rater 1	1	0.93 (0.84-0.97)	1.1	3.0	0.93 (0.82-0.97)	1.3	3.6
	2 (mean)	0.98 (0.95-0.99)	0.6	1.6	0.96 (0.91-0.98)	0.9	2.6
	3 (mean)	0.97 (0.94-0.99)	0.7	1.9	0.97 (0.92-0.98)	0.8	2.3
	4 (mean)	0.97 (0.94-0.99)	0.7	1.9	0.97 (0.93-0.99)	0.8	2.2
	5 (mean)	0.98 (0.94-0.99)	0.6	1.6	0.97 (0.94-0.99)	0.8	2.2
	6 (mean)	0.98 (0.94-0.99)	0.6	1.6	0.98 (0.94-0.99)	0.7	1.8
Intra-rater 2	1	0.52 (0.09-0.79)	2.8	7.9	0.74 (0.44-0.89)	2.5	7.1
	2 (mean)	0.73 (0.29-0.90)	2.2	6.0	0.86 (0.62-0.94)	1.8	5.1
	3 (mean)	0.77 (0.39-0.91)	2.0	5.6	0.86 (0.64-0.95)	1.8	5.1
	4 (mean)	0.79 (0.45-0.92)	1.9	5.3	0.87 (0.66-0.95)	1.8	4.9
	5 (mean)	0.80 (0.46-0.92)	1.9	5.2	0.87 (0.66-0.95)	1.8	4.9
	6 (mean)	0.81 (0.49-0.93)	1.8	5.1	0.87 (0.67-0.95)	1.8	4.9

Notes: Reliability is presented separately for two raters: Intra-rater 1 (repeated measurements within the same day) and Intra-rater 2 (measurements repeated after a one-week interval). The column "N registrations" indicates the number of US images averaged to calculate each value. ICC – intraclass correlation coefficient, SDD – smallest detectable differences, SEM – standard errors of measurement.

The mean registered VM thickness at rest was 27.1 mm ( $\pm$ 3.9), increasing to 32.4 mm ( $\pm$ 4.6) during MVIC, with a mean thickness change of 5.3 mm ( $\pm$ 2.5). VM thickness results during rest and MVIC for individual participants are presented in Table 2.

**Table 2.** VM thickness measurement during rest and MVIC for individual participants (mean of all 18 registrations recorded during three sessions of the of the study)

Participant no.	Rest (mm)	MVIC (mm)	VM thickness change (mm)
1	29.3	31.9	2.6
2	30.9	32.2	1.3
3	28.8	42.1	13.3
4	23.3	29.8	6.5
5	29.7	32.9	3.2
6	27.2	30.9	3.7
7	27.4	31.7	4.3
8	33.7	37.9	4.2
9	24.3	30.5	6.2
10	28.6	35.7	7.1
11	33.8	40.9	7.1
12	20.1	26.1	6.0
13	24.5	27.5	3.0
14	25.4	31.7	6.3
15	22.6	26.7	4.1
16	31.3	37.6	6.3
17	24.1	29.5	5.4
18	22.6	28.5	6.4
<b>Mean (SD)</b>	27.1 ( $\pm$ 3.9)	32.4 ( $\pm$ 4.6)	5.3 ( $\pm$ 2.5)
<b>Min-max</b>	20.1 to 33.8	26.1 to 42.1	1.3 to 13.3

Notes: SD – standard deviation. Mean values, SDs, and ranges are presented.

## Discussion

This study demonstrates that intra-rater reliability for VM thickness measurements in the longitudinal plane using US depends on the number of registrations and measurement conditions. Intra-rater 1 reliability showed consistently excellent ICC values ( $\geq 0.93$ ) for both R and MVIC conditions, indicating strong reliability for same-session measurements. In contrast, intra-rater 2 reliability was lower, particularly for single registrations, highlighting the challenges of reproducing VM thickness measurements over a one-week interval. ICC values for R measurements ranged from moderate (0.52) to good (0.81), suggesting variability due to probe positioning, participant differences, and examiner experience. However, averaging registrations significantly improved reliability (ICC up to 0.87), emphasizing the importance of careful methodological approaches. These findings are consistent with prior research; Koen et al. found good test-retest reliability of VM thickness across knee flexion angles [23]. Worsley et al. validated US against MRI for distal VM fibers, demonstrating high correlations (ICC: 0.84-0.94) and strong associations between thickness and CSA ( $r=0.87$ ) [20]. Taniguchi et al. found better US-MRI correlations for VM thickness in the sitting position [4], while Minnehan et al. demonstrated excellent US-MRI agreement for VM CSA (ICC: 0.980-0.997) [21]. Cheon et al. showed moderate-to-high inter-rater reliability for VM thickness (ICC: 0.62-0.90) [26], further supporting the validity of US for VM assessments. Accurate VM thickness assessment is clinically relevant for conditions such as PFPS, knee osteoarthritis, and post-surgical quadriceps dysfunction. High intra-rater reliability underscores the utility of US in VM evaluation, with multiple

measurements enhancing diagnostic accuracy, and despite lower intra-rater 2 reliability, averaging ensured acceptable reliability, highlighting the need for consistent landmarks, standardized protocols, and examiner training for effective long-term clinical monitoring.

This study has several limitations. The small sample of healthy participants (83% females) limits generalizability to clinical populations. Future studies should investigate both genders in balanced groups and extend the research to various populations (e.g. patients with PFPS, knee OA, and post-ACL reconstruction). Additionally, the limited sonographic experience of the examiner may have influenced reliability, suggesting the need to investigate the effects of examiner expertise and the potential benefits of advanced training programs. Future studies should investigate reliability across different levels of clinical experience, explore automation-assisted US techniques, and assess the utility of VM thickness measurements in monitoring treatment outcomes.

## Conclusions

In conclusion, VM thickness measurements using US imaging in the longitudinal plane are highly reliable within a single session, particularly when multiple registrations are averaged. Although reliability decreases over a one-week interval, repeated measurements can improve consistency. For progress monitoring in clinical practice, at least 3-4 images should be averaged, and changes smaller than ~5-8 mm (depending on conditions and number of images) should be interpreted with caution. These findings support using US as a reliable tool for assessing VM thickness in the longitudinal plane in clinical and research settings.

## Disclosures and acknowledgements

The authors declare no conflicts of interest with respect to the research, authorship, and/or publication of this article.

This research received no specific grant from any funding agency in the public, commercial, or not-for-profit sectors.

The study received the ethical approval (the approval number: 2017/3) from the Research Ethics Committee at Academy of Physical Education, Katowice, Poland. The recruitment took place between March 2017 and May 2021. All the participants were provided with the written informed consent. The Declaration of Helsinki was followed in the conduct of the study.

Artificial intelligence software (Grammarly, Inc., San Francisco, CA, USA) was utilized only for the grammar and vocabulary correction during the initial preparation of the article draft and did not generate scientific content.

## References:

1. Sakai N, Luo ZP, Rand JA, An KN. The influence of weakness in the vastus medialis oblique muscle on the patellofemoral joint: an in vitro biomechanical study. *Clin Biomech (Bristol, Avon)*. 2000; 15(5): 335-339. [https://doi.org/10.1016/S0268-0033\(99\)00089-3](https://doi.org/10.1016/S0268-0033(99)00089-3)
2. Loudon JK. Biomechanics and pathomechanics of the patellofemoral joint. *Int J Sports Phys Ther*. 2016; 11(6): 820-830.

3. Kumar D, Link TM, Jafarzadeh SR, LaValley MP, Majumdar S, Souza RB. Association of quadriceps adiposity with an increase in knee cartilage, meniscus, or bone marrow lesions over three years. *Arthritis Care Res (Hoboken)*. 2021; 73(8): 1134-1139. <https://doi.org/10.1002/acr.24232>
4. Taniguchi M, Fukumoto Y, Yagi M, Motomura Y, Okada S, Okada S, et al. Enhanced echo intensity in vastus medialis is associated with worsening of functional disabilities and symptoms in patients with knee osteoarthritis: a 3 years longitudinal study. *Rheumatol Int*. 2023; 43(5): 953-960. <https://doi.org/10.1007/s00296-022-05246-6>
5. Giles LS, Webster KE, McClelland JA, Cook J. Does quadriceps atrophy exist in individuals with patellofemoral pain? A systematic literature review with meta-analysis. *J Orthop Sports Phys Ther*. 2013; 43(11): 766-776. <https://doi.org/10.2519/jospt.2013.4833>
6. Pattyn E, Verdonk P, Steyaert A, Vanden Bossche L, Van den Broecke W, Thijs Y, et al. Vastus medialis obliquus atrophy: does it exist in patellofemoral pain syndrome?. *Am J Sports Med*. 2011; 39(7): 1450-1455. <https://doi.org/10.1177/0363546511401183>
7. Amestoy J, Pérez-Prieto D, Torres-Claramunt R, Sánchez-Soler JF, Solano A, Leal-Blanquet J, et al. Preoperative muscle thickness influences muscle activation after arthroscopic knee surgery. *Knee Surg Sports Traumatol Arthrosc*. 2022; 30(6): 1880-1887. <https://doi.org/10.1007/s00167-021-06820-4>
8. Rice DA, McNair PJ. Quadriceps arthrogenic muscle inhibition: neural mechanisms and treatment perspectives. *Semin Arthritis Rheum*. 2010; 40(3): 250-266. <https://doi.org/10.1016/j.semarthrit.2009.10.001>
9. McPherson AL, Schilaty ND, Anderson S, Nagai T, Bates NA. Arthrogenic muscle inhibition after anterior cruciate ligament injury: injured and uninjured limb recovery over time. *Front Sports Act Living*. 2023; 5: 1143376. <https://doi.org/10.3389/fspor.2023.1143376>
10. Lepley AS, Lepley LK. Mechanisms of arthrogenic muscle inhibition. *J Sport Rehabil*. 2021; 31(6): 707-716. <https://doi.org/10.1123/jsr.2020-0479>
11. Biały M, Kublin K, Brzuszkiewicz-Kuźmicka G, Gnat R. Myofascial and movement tests after anterior cruciate ligament reconstruction. *J Hum Kinet*. 2022; 83: 67-75. <https://doi.org/10.2478/hukin-2022-0052>
12. Biały M, Kublin K, Wilczyński B, Forelli F, Gnat R. Does concomitant meniscectomy or meniscus repair affect muscle strength, lower extremity balance, and functional tests after anterior cruciate ligament reconstruction?. *J Clin Med*. 2024; 13(11): 3310. <https://doi.org/10.3390/jcm13113310>
13. Narici M, Cerretelli P. Changes in human muscle architecture in disuse-atrophy evaluated by ultrasound imaging. *J Gravit Physiol*. 1998; 5(1): P73-P74.
14. Krishnan C, Williams GN. Factors explaining chronic knee extensor strength deficits after ACL reconstruction. *J Orthop Res*. 2011; 29(5): 633-640. <https://doi.org/10.1002/jor.21316>
15. Dauty M, Menu P, Mesland O, Fouasson-Chailloux A. Arthrogenic muscle inhibition and return to sport after arthrofibrosis complicating anterior cruciate ligament surgery. *Eur J Sport Sci*. 2022; 22(4): 627-635. <https://doi.org/10.1080/17461391.2021.1881620>
16. Gnat R, Saulicz E, Miądowicz B. Reliability of real-time ultrasound measurement of transversus abdominis thickness in healthy trained subjects. *Eur Spine J*. 2012; 21: 1508-1515. <https://doi.org/10.1007/s00586-012-2184-4>

17. Gogola A, Gnat R, Zaborowska M, Dziub D, Gwozdz M. Asymmetry of activation of lateral abdominal muscles during the neurodevelopmental traction technique. *J Bodyw Mov Ther.* 2018; 22(1): 46-51. <https://doi.org/10.1016/j.jbmt.2017.03.019>
18. Stokes T, Tripp TR, Murphy K, Morton RW, Oikawa SY, Choi HL, et al. Methodological considerations for and validation of the ultrasonographic determination of human skeletal muscle hypertrophy and atrophy. *Physiol Rep.* 2021; 9(1): e14683. <https://doi.org/10.14814/phy2.14683>
19. Biały M, Adamczyk WM, Stranc T, Gogola A, Gnat R. The association between pelvic asymmetry and lateral abdominal muscle activity in a healthy population. *J Hum Kinet.* 2024; 97: 77-87. <https://doi.org/10.5114/jhk/191098>
20. Worsley PR, Kitsell F, Samuel D, Stokes M. Validity of measuring distal vastus medialis muscle using rehabilitative ultrasound imaging versus magnetic resonance imaging. *Man Ther.* 2014; 19(3): 259-263. <https://doi.org/10.1016/j.math.2014.02.002>
21. Minnehan KS, Dexter WW, Holt CT, Scharnetzki L, Alex JP, Chin KE, et al. Validation of panoramic ultrasound measurement of the cross-sectional area of the vastus medialis. *J Strength Cond Res.* 2023; 37(1): 41-45. <https://doi.org/10.1519/JSC.0000000000004196>
22. Abiko T, Ohmae K, Murata S, Shiraiwa K, Horie J. Reliability of muscle thickness and echo intensity measurements of the quadriceps: a novice examiner. *J Bodyw Mov Ther.* 2022; 31: 164-168. <https://doi.org/10.1016/j.jbmt.2022.03.004>
23. Koen S, Sutherlin M, Saliba M, Hart J. Reliability of ultrasound image-based measurements of the vastus medialis oblique muscle structure and function. *Athletic Training & Sports Health Care.* 2018; 10(5): 217-226. <https://doi.org/10.3928/19425864-20180306-03>
24. [www.seniam.org](http://www.seniam.org) [Internet]. The SENIAM project (Surface ElectroMyoGraphy for the Non-Invasive Assessment of Muscles). European concerted action in the Biomedical Health and Research Program (BIOMED II) of the European Union [access 2017 March]. Available from: <http://www.seniam.org>
25. Koo TK, Li MY. A guideline of selecting and reporting intraclass correlation coefficients for reliability research. *J Chiropr Med.* 2016; 15: 155-163. <https://doi.org/10.1016/j.jcm.2016.02.012>
26. Cheon S, Chang E. Inter-rater reliability of a portable ultrasound for the quadriceps and hamstrings thickness measurement in healthy adults. *Exerc Sci.* 2020; 29: 71-76. <https://doi.org/10.15857/ksep.2020.29.1.71>